

Approach to a case of GUTB

D. Dalela
M.S., M.Ch, FICS, FAMS

Professor
Department of Urology
K G Medical University
Lucknow

Diagnosis Making **Treatment Planning**

Diagnosis Making

1 Is the patient having GUTB

- Clinical Dx
- Laboratory Dx

Diagnosis Making

2 What sites in genitourinary tract are involved?

- Urinary
 - UUT
 - LUT
- Genital

Diagnosis Making

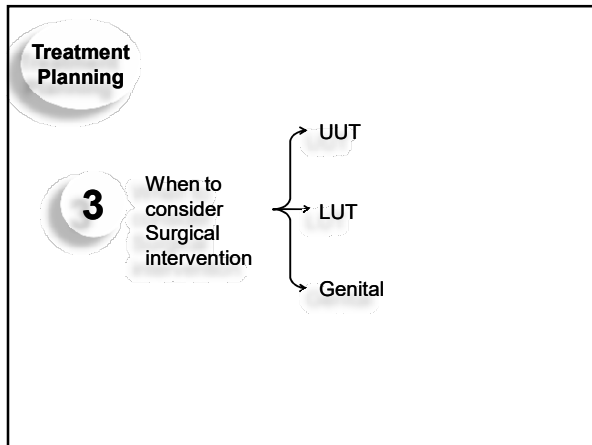
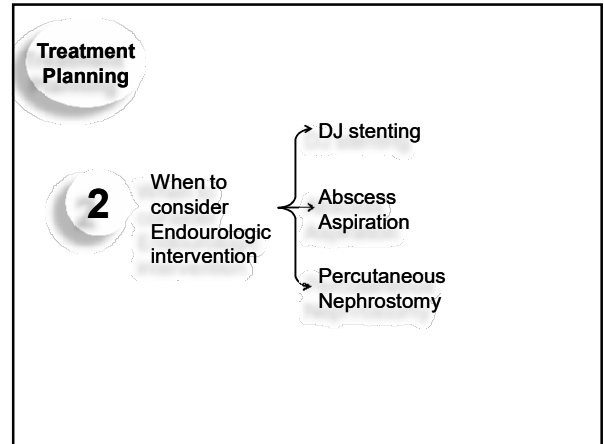
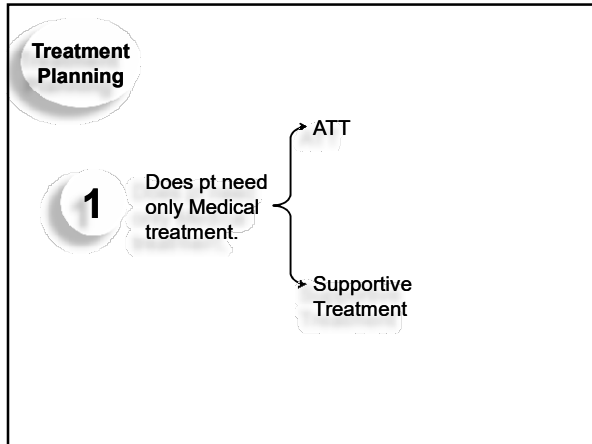
3 What is Severity of involvement?

- A** Pathological Damage
 - Early, non-caseous
 - Caseous
 - Late, calcified
- B** Virulence of Bacilli
 - Primary
 - Recurrent/Resistant

Diagnosis Making

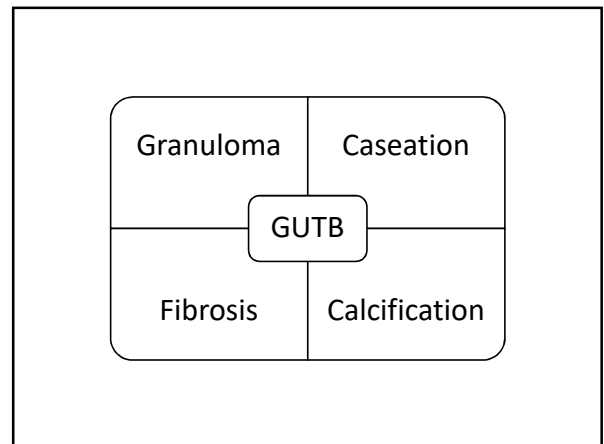
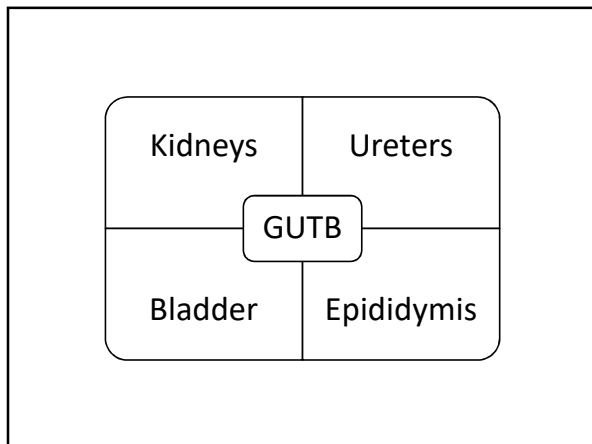
4 What is Degree of functional impairment?

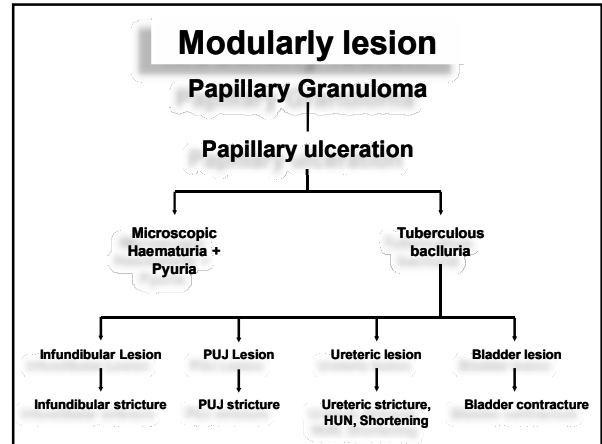
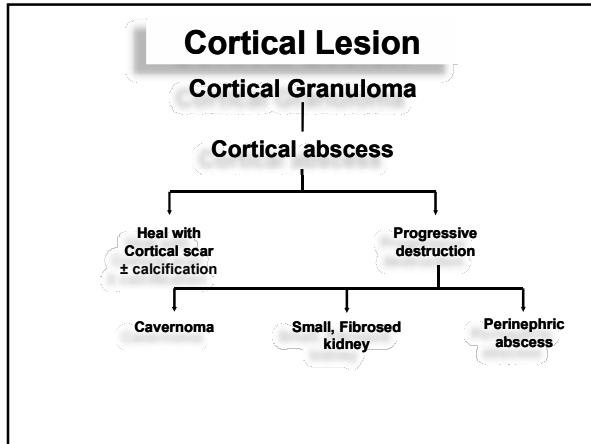
- Urinary tract
 - UUT
 - LUT
- Genital tract



PART -1

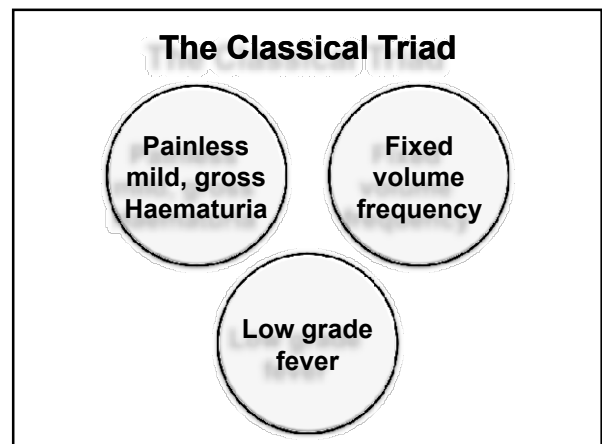
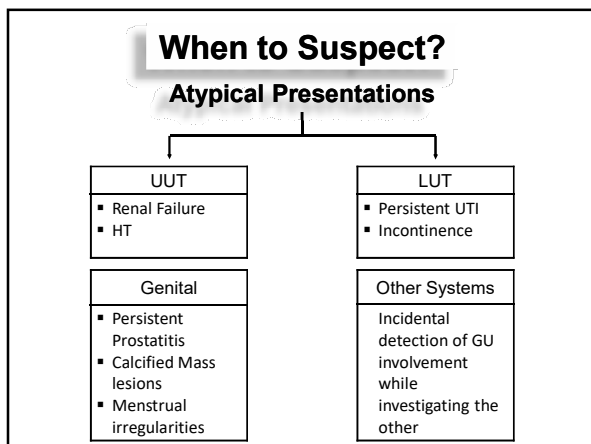
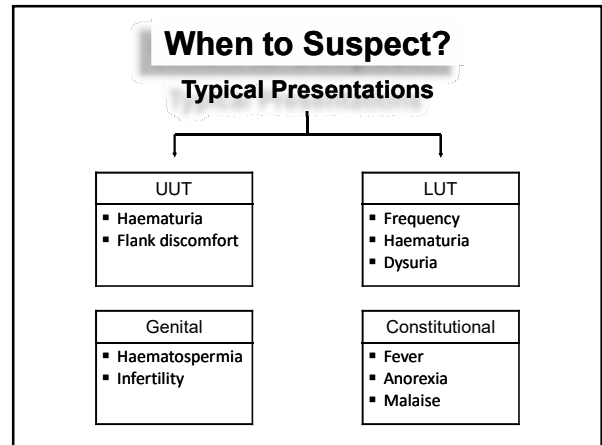
Progression of GUTB

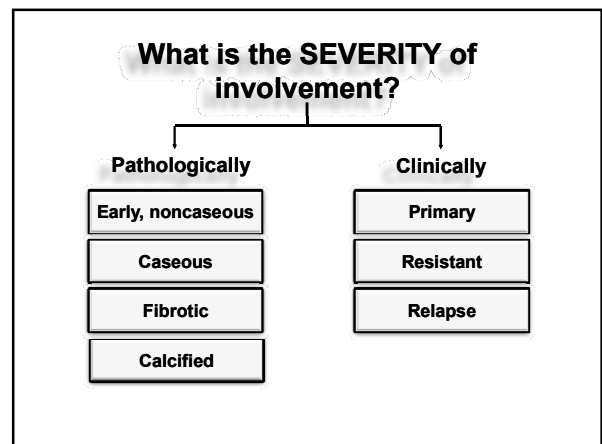
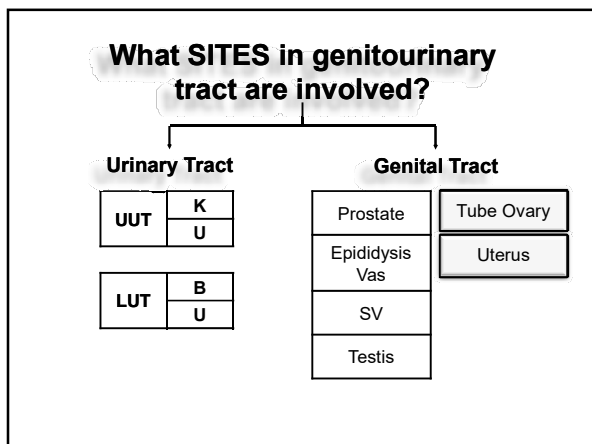
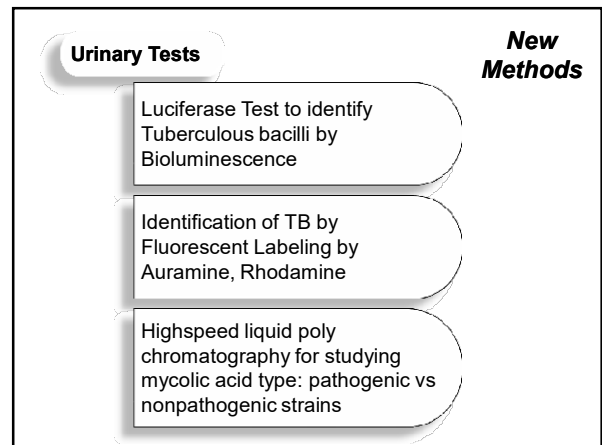
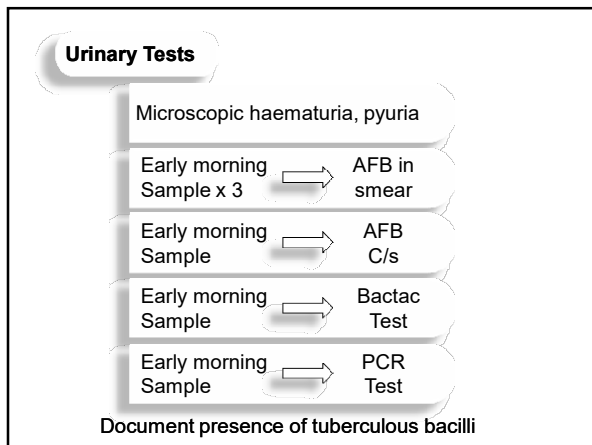
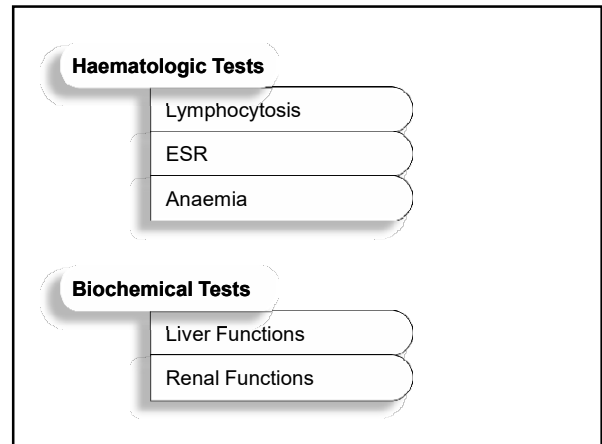
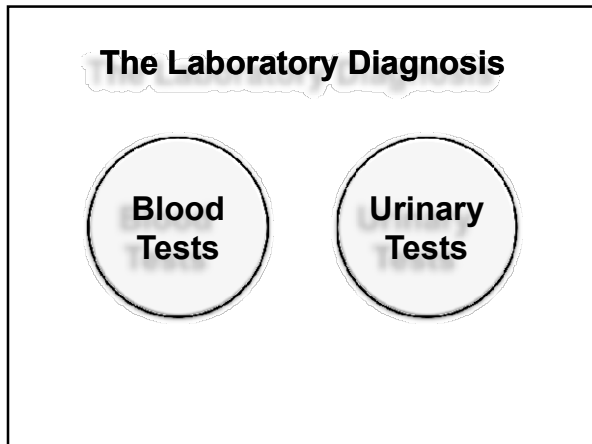


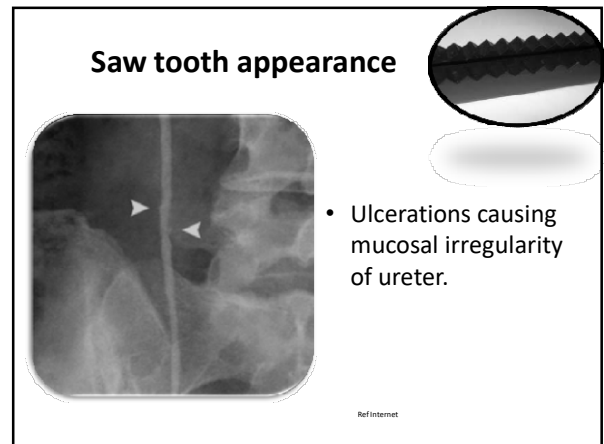
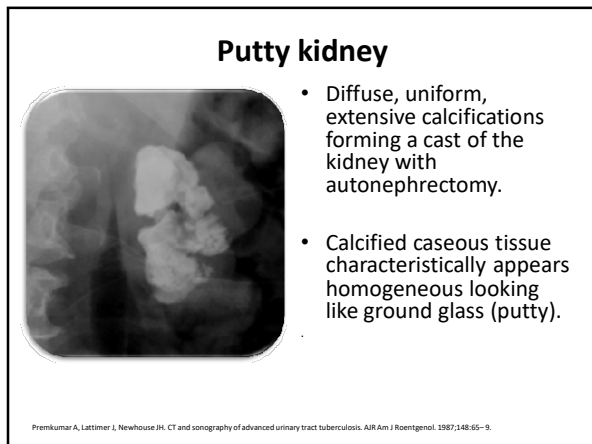
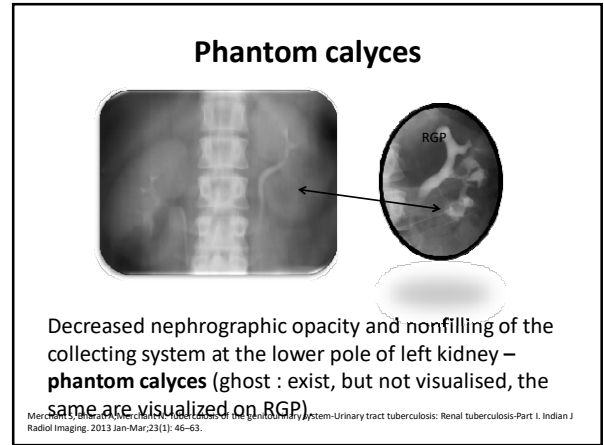
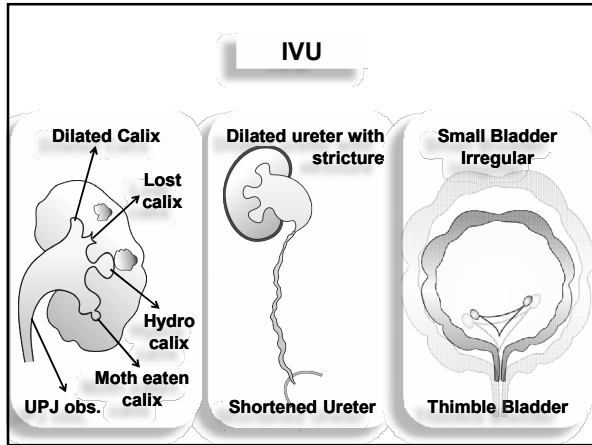
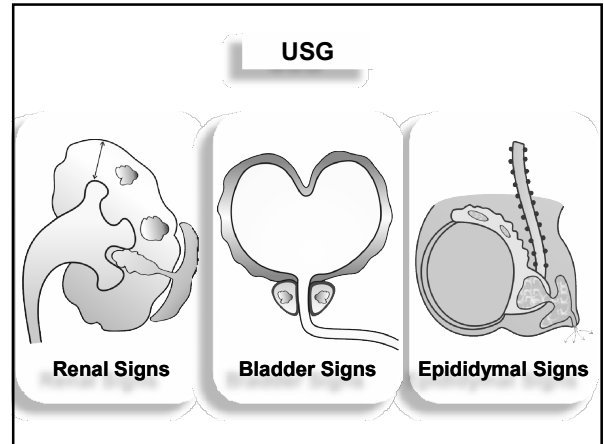
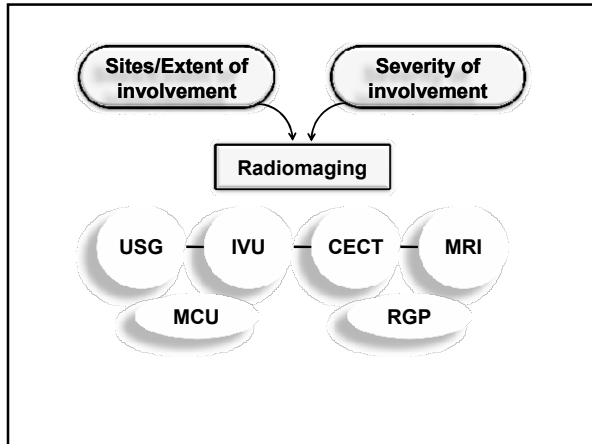


PART -2


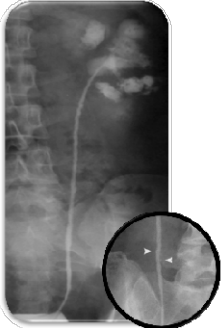
Diagnosis
 Making of a case suspected to be having GUTB



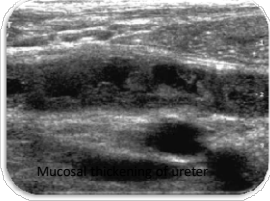




Beaded / Corkscrew ureter


- Fusion of multiple strictures may create a long, irregular narrowing. Several nonconfluent strictures can produce a "beaded" or "corkscrew" ureter




Mucosal stricture of ureter

RefInternet

Corkscrew ureter

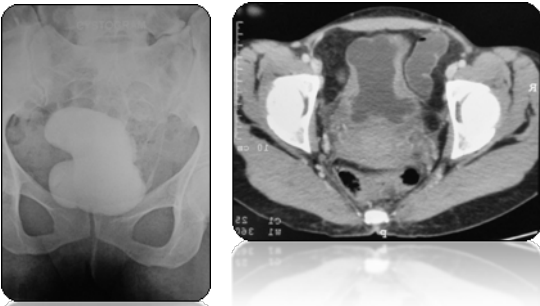


Pipe stem ureter





- Rigid ureter: irregular and lacks normal anatomical curves and the peristaltic movement, fibrotic strictures noted.
- Note the distortion, amputation and irregularity of the upper pole calices.

Hour Glass Bladder



Thimble bladder

Diminutive and irregular urinary bladder – simulating a thimble.

